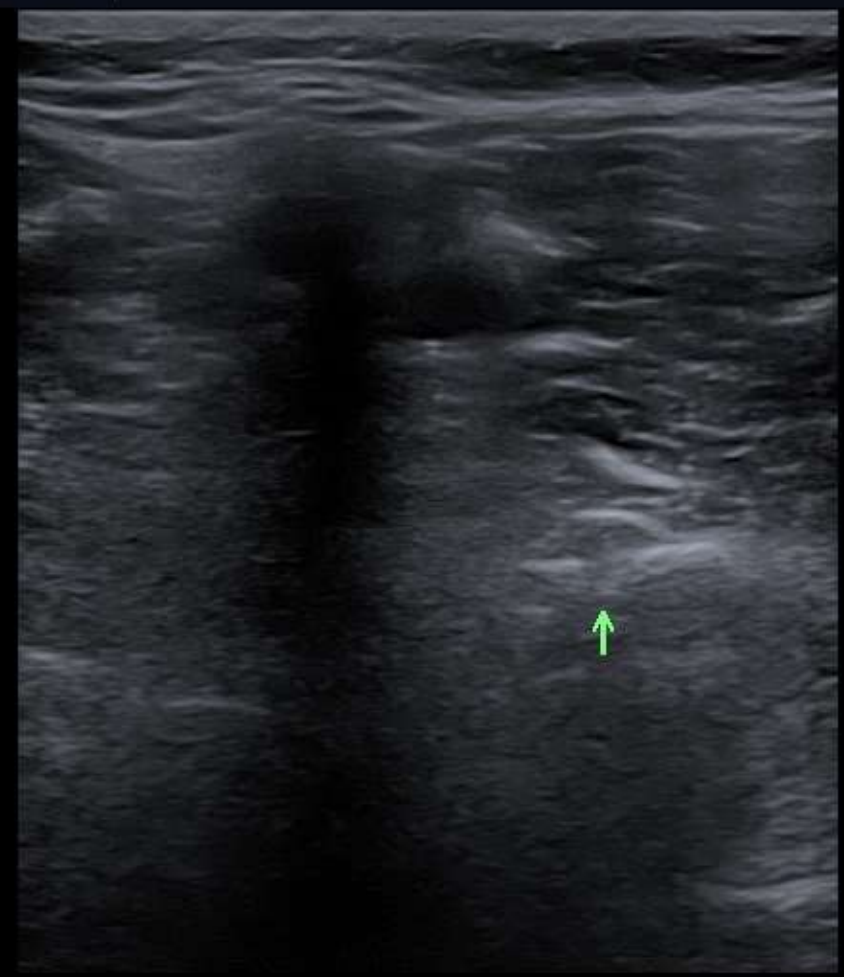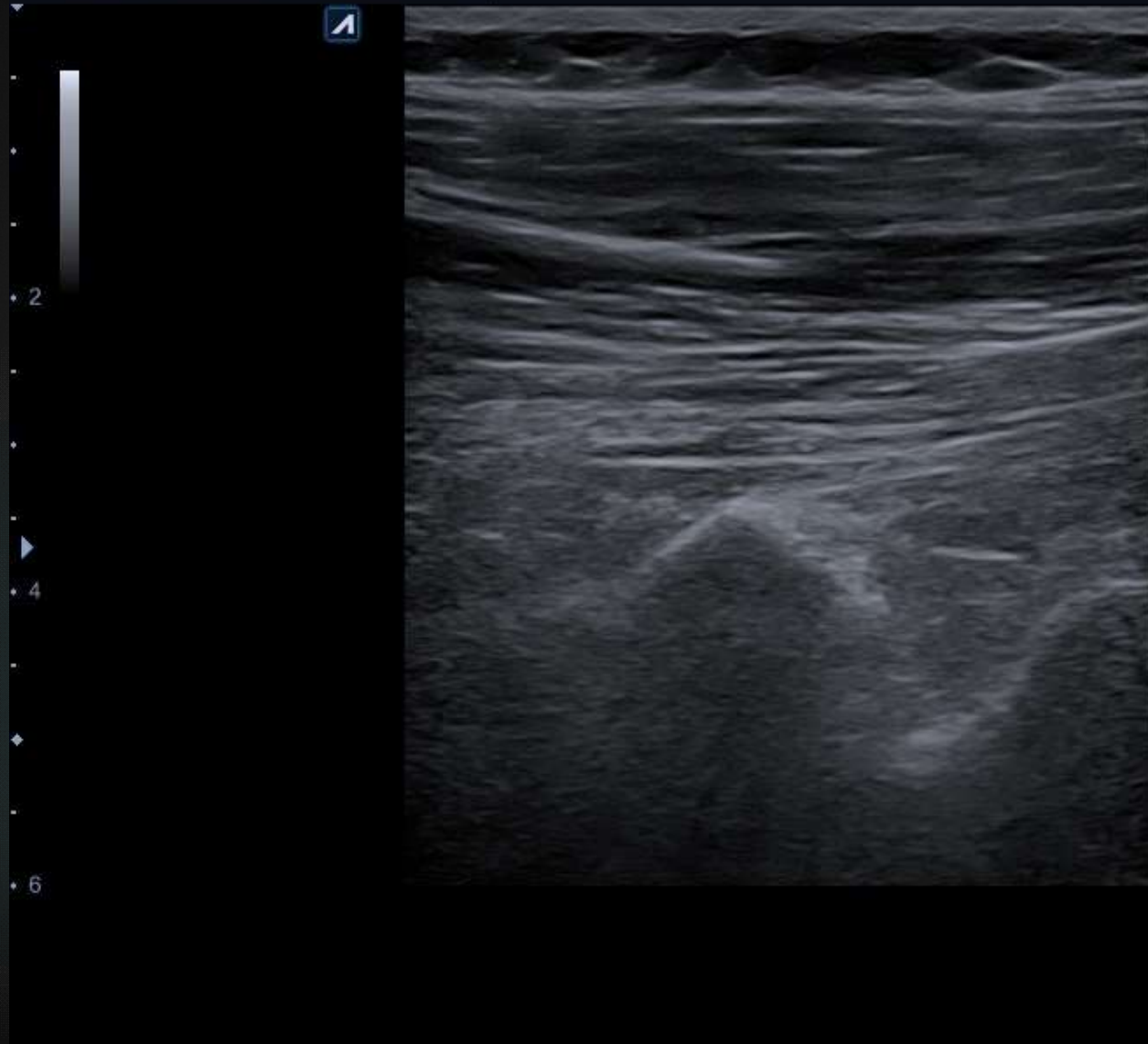


Kręgosłup Obraz w USG

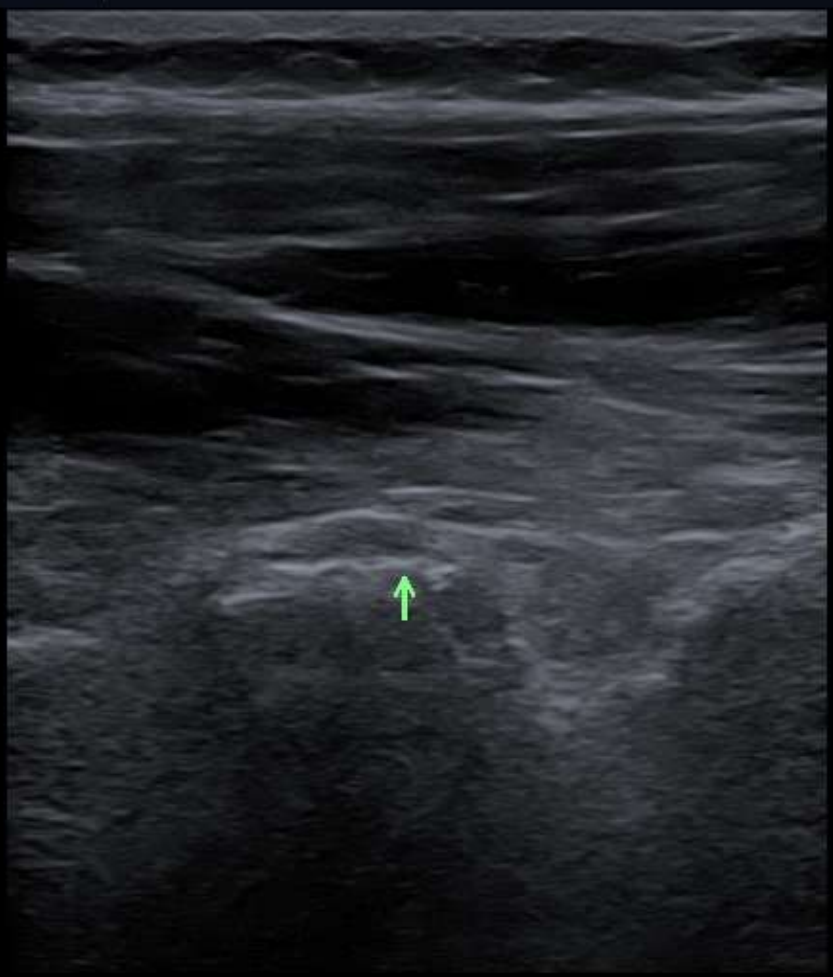TOMASZ POBOŻY




MSK
2D
P 90%
Frq 6.5
Gn 48
DR 74
FR 31
D 6.0

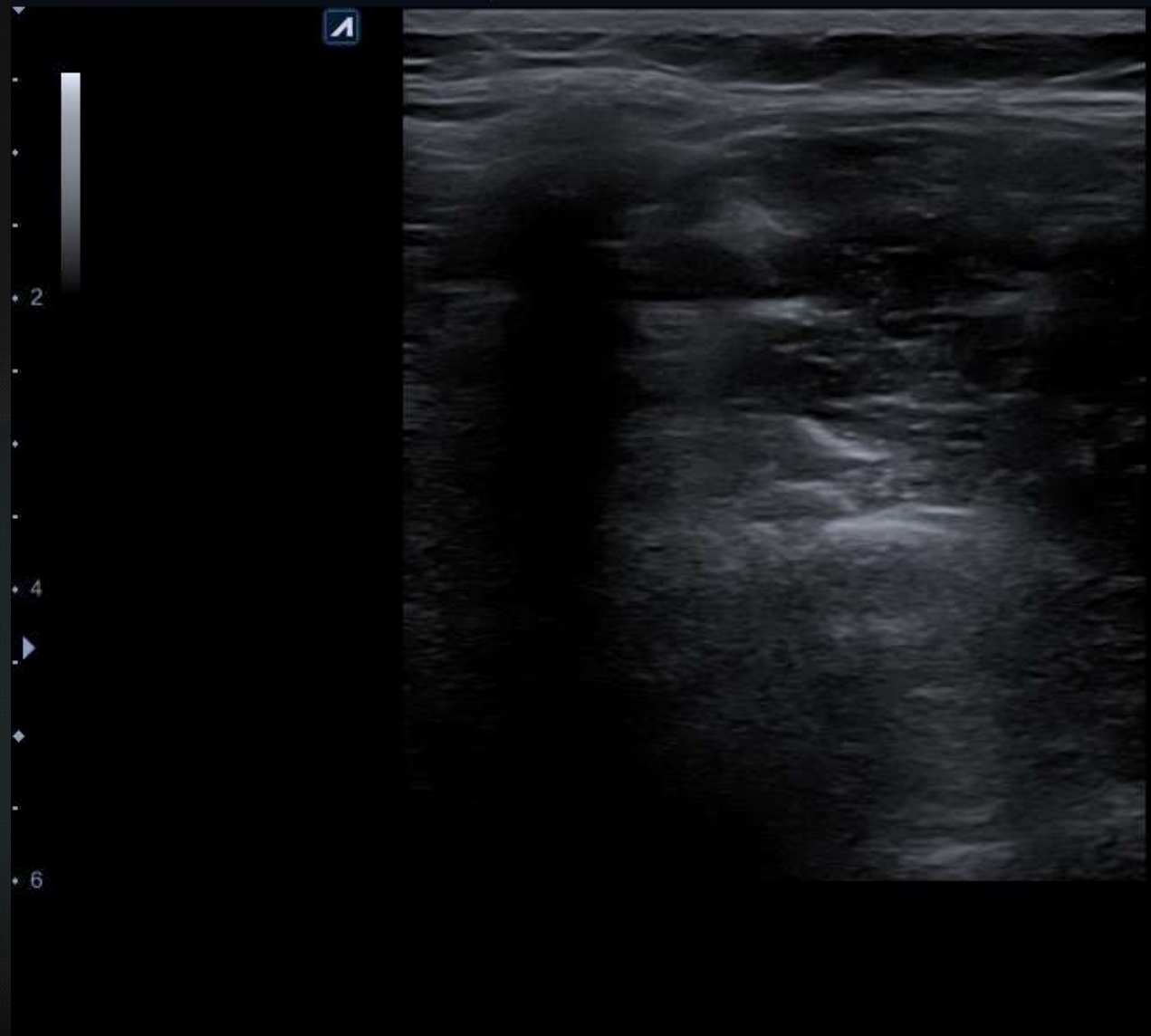

MSK
2D
P 90%
Frq 6.5
Gn 45
DR 74
FR 31
D 6.0

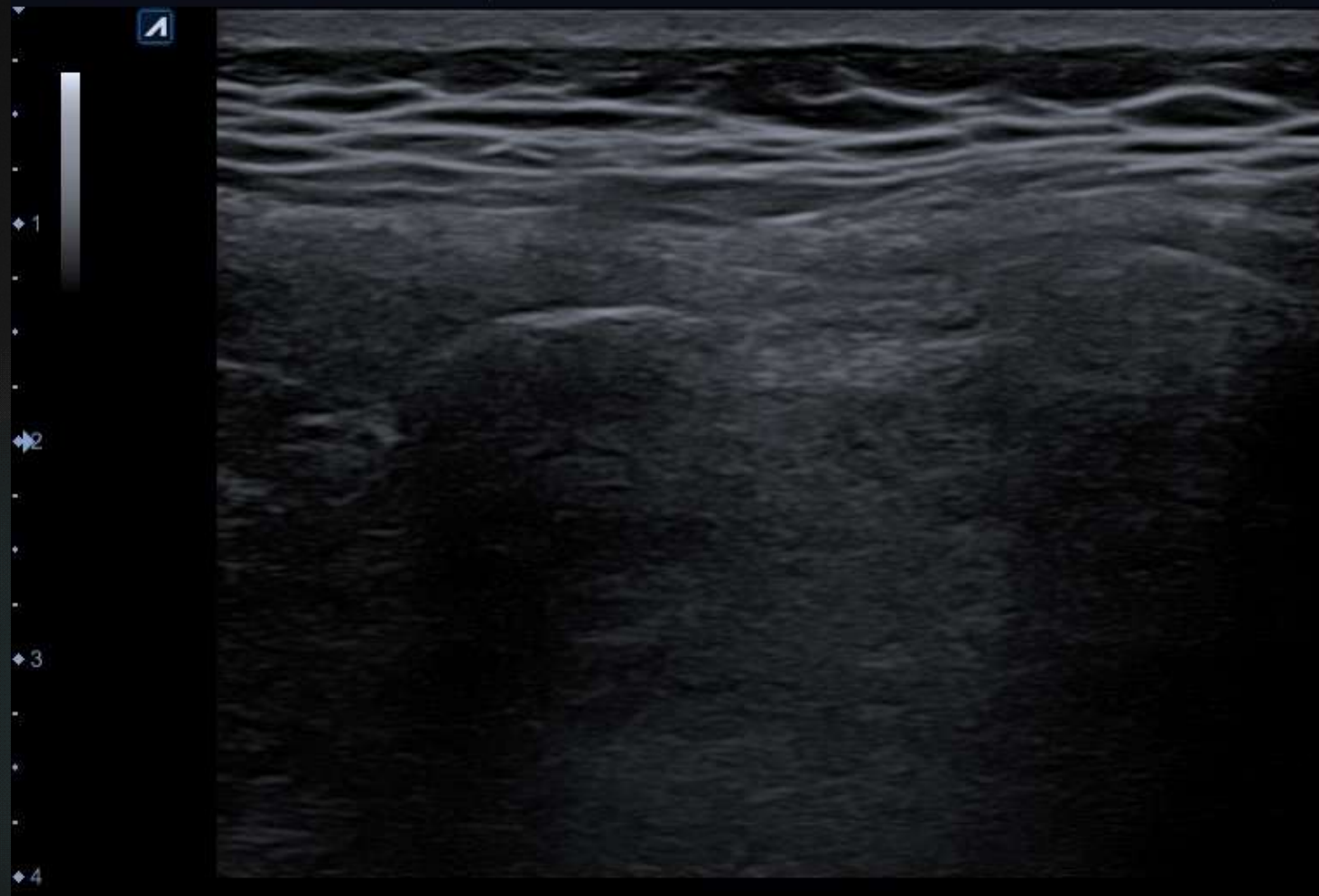


MSK
2D
P 90%
Frq 6.5
Gn 45
DR 74
FR 31
D 6.0

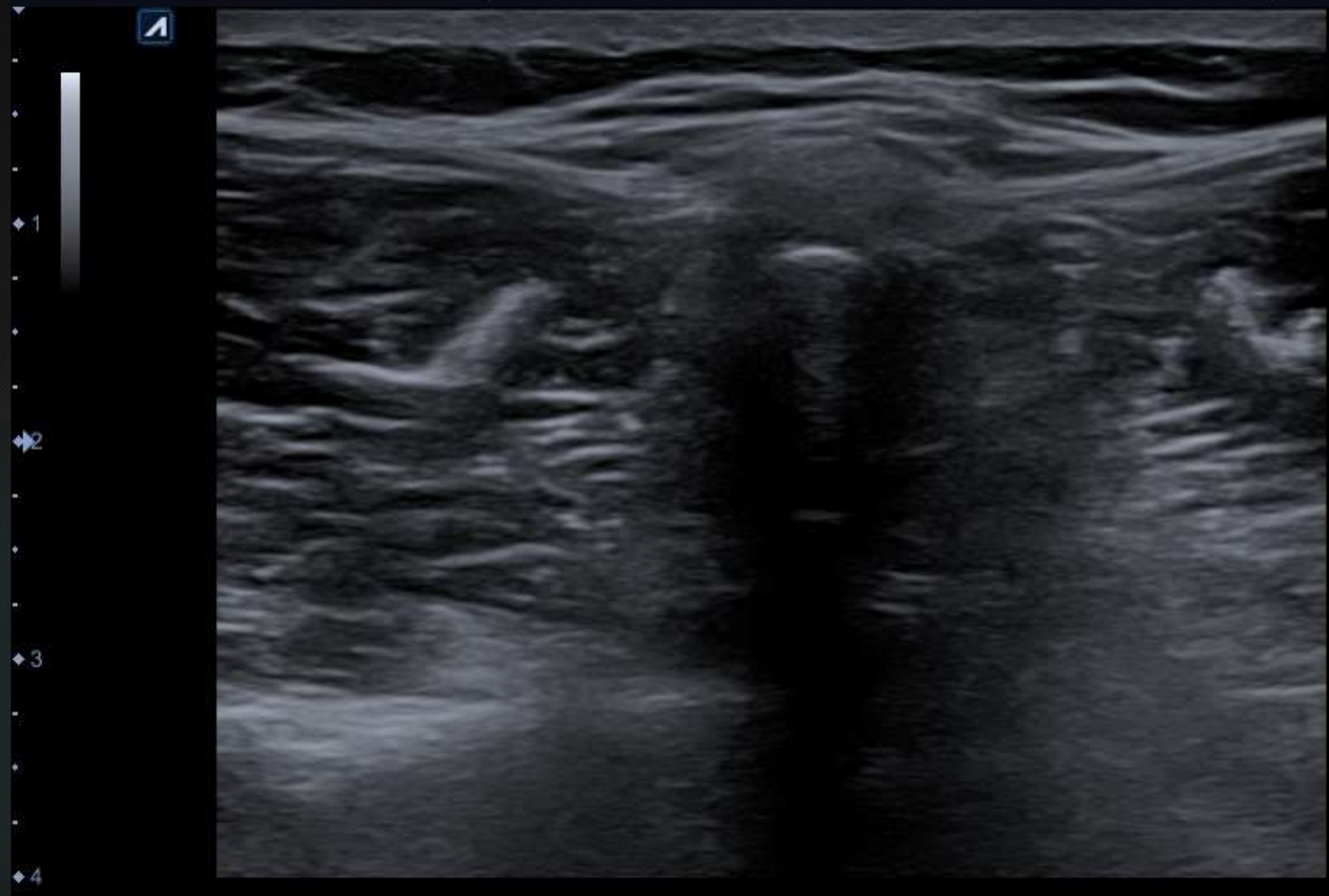




MSK
2D
P 90%
Frq 6.5
Gn 45
DR 74
FR 31
D 6.0



MSK
2D
P 90%
Frq 6.5
Gn 45
DR 74
FR 37
D 4.0



MSK
2D
P 90%
Frq 8.5
Gn 45
DR 74
FR 37
D 4.0



